
Isolation of subgenus B adenovirus during a fatal outbreak of enterovirus 71-associated hand, foot, and mouth disease in Sibü, Sarawak

M Jane Cardosa, Shekhar Krishnan, Phaik Hooi Tio, David Perera, See Chang Wong

Summary

Background In mid-1997, several children died in Sarawak, Malaysia, during an epidemic of enterovirus-71 (EV71) hand, foot, and mouth disease. The children who died had a febrile illness that rapidly progressed to cardiopulmonary failure and the cause was not satisfactorily resolved. We describe the isolation and identification of a subgenus B adenovirus from the children who died.

Methods We studied two groups of children presenting to Sibü Hospital from April 14 to Sept 30, 1997. For children who died, the inclusion criterion was death after febrile illness, and for those who did not die it was acute flaccid paralysis (AFP). Serum and cerebrospinal fluid samples were tested for IgM antibodies to Japanese encephalitis and dengue viruses. Viruses isolated were identified by immunofluorescence, reverse-transcriptase PCR, or PCR and DNA sequencing.

Findings Enterovirus was isolated in three (19%) of 16 children who died and in none of the eight surviving children with AFP. However, an agent that was initially difficult to identify was found in ten (63%) children who died and five (63%) surviving children who had AFP. The agents isolated from ten (66.7%) of these 15 children were eventually identified as adenoviruses and were isolated mainly from clinically important sterile sites or tissues. All the enterovirus-positive children who died had this second agent.

Interpretation Our data raises doubts that EV71 was the only aetiological agent in these deaths.

Lancet 1999; **354**: 987–91

Introduction

On April 14, 1997, a boy aged 19 months presented with acute shock after a brief unremarkable febrile illness. Acute myocardial dysfunction with cardiogenic shock was suspected when fluid resuscitation led to pulmonary oedema and echocardiogram showed a poorly contractile globular left ventricle. During the next 4–5 months, several children presented with a brief prodromal febrile illness followed by rapid deterioration with cardiogenic shock and death refractory to supportive care.

Two children, who were among the first to die, had acute flaccid paralysis (AFP). Concurrently, a greater number than normal (two or three cases a year) of polio-vaccinated children with uncomplicated AFP was noted. The temporal association of acute myocardial dysfunction with AFP and aseptic meningitis in the context of hand, foot, and mouth disease suggested a major enterovirus epidemic in the community, and formal epidemiological and virological investigations were started by the Sarawak Health Department at the end of May, 1997.

It has been 2 years since this cluster of paediatric deaths occurred in Sarawak, Malaysia.^{1,2} The deaths of at least 34 children aged 5 months to 7 years (mean age 20 months) were reported during a period of less than 5 months. However, a clear consensus on cause has been difficult to reach because the unusual presentation of cardiomyopathy with encephalitis occurred against a background of enterovirus-71 (EV71) hand, foot, and mouth disease (seven of 12 enteroviruses isolated from children with this disease were EV71; unpublished data). A similar episode took place a year ago in Taiwan and the aetiological agent associated with the deaths is still under investigation.³

We will focus on patients admitted to Sibü Hospital, the only hospital serving Sibü town, where this unusual outbreak was first recognised and where 20 of the 34 recorded child deaths occurred. Sibü town has a population of 200 000 and is situated at the gateway to the Rejang Valley in the heart of Sarawak. The hospital also serves as a referral hospital for smaller district hospitals in the Rejang basin. The first nine deaths in the Sarawak outbreak occurred in Sibü Hospital, with Sibü town as the epicentre of the outbreak which, by mid June, had spread to other parts of Sarawak.

Methods

We included two groups of patients in our study: children in whom unexplained sudden paediatric death after a febrile illness was the only inclusion criterion, and children with AFP during the outbreak who did not die. Both groups were admitted to Sibü Hospital from April 14 to the end of September, 1997.

Samples obtained were mainly from serum, cerebrospinal fluid, throat swabs, and rectal swabs. These samples were inoculated onto or cocultivated with monolayers of rhabdomyosarcoma (RD) cells, human pulmonary adenocarcinoma (A549) cells, African green-monkey kidney (Vero) cells, and *Aedes albopictus* (C6/36) cells in flat tissue-culture tubes (Nunc, Roskilde, Denmark), and

Institute of Health and Community Medicine, Universiti Malaysia Sarawak, 94300 Kota Samarahan, Sarawak, Malaysia

(M J Cardosa DPhil, Phaik Hooi Tio MSc, D Perera MSc); and Sibü Hospital, Sibü, Sarawak (S Krishnan MRCP, See Chang Wong MRCP)

Correspondence to: Dr M Jane Cardosa
(e-mail: jcardosa@mailhost.unimas.my)

observed daily for cytopathic effect. All cultures were subjected to one blind passage in the same four cell lines. We used PCR or reverse-transcriptase (RT) PCR to identify cultures that were positive for enterovirus or adenovirus. RT-PCR was used to identify flaviviruses only if a characteristic cytopathic effect was seen in C6/36 cells. Direct immunofluorescence for adenovirus and herpes simplex virus types 1 and 2 was done with Dako Imagen reagents (Ely, UK).

Viral nucleic acids were extracted from freeze-thawed cultures by QIAamp viral RNA kit (Qiagen, Hilden, Germany) or a high pure viral nucleic-acid extraction kit (Boehringer Mannheim, Mannheim, Germany) and were used as templates for RT-PCR or PCR. The oligonucleotide primers used were based on previously published sequences⁴⁻⁶ and were synthesised by Genemed Synthesis (San Francisco, CA, USA). For adenovirus identification, the forward primer was 5'-GCCG CAGTGGTCTTACATGCACATC-3' and the reverse primer was 5'-CAGCACGCCGCGGATGTCAAAGT-3', which gave an expected product size of 301 bp.⁴ For enterovirus identification, the forward primer was 5'-ATTGTACCATAAGCAGCCA-3' and the reverse primer was 5'-CCTCCGGCCCTGAATGCGGCTAAT-3', which gave a product of 154 bp.⁵ The presence of flavivirus genome was detected by universal flavivirus primers that were expected to give variable product sizes depending on the flavivirus. The forward primer was 5'-GGTCTCCTCTAACCTCTAG-3' and the reverse primer was 5'-GAGTGGATGACCACGGAAGACATGC-3'.⁶ The cycling conditions used for amplification have been described previously (unless stated otherwise).⁶

EV71 was identified by oligonucleotide primers (cycling conditions generously provided by M Pallansch, CDC, Atlanta, GA, USA). We also submitted some adenoviruses and non-EV71 enteroviruses to the pathology department of Singapore General Hospital for typing by standard neutralisation assays. Some cultures were positive for adenoviruses by immunofluorescence, but the viruses were difficult to grow sufficiently well for neutralisation tests. PCR products from these fastidious adenoviruses that were identified were cloned by use of the Zero Blunt cloning kit (Invitrogen, Carlsbad, CA, USA) and inserts were sequenced in both directions by a sequencing service (ACGT, Northbrook, IL, USA) by ABI-100 version 3.0. All serum and cerebrospinal-fluid samples were tested for IgM antibodies to Japanese encephalitis and dengue viruses.^{7,8} We further characterised three of the fastidious adenoviruses by restriction digestion of a virus-associated (VA) RNA gene region PCR product using previously described methods.⁹

Results

We obtained specimens from 16 of the 20 children who died and from all of the eight surviving children with AFP seen in Sibul Hospital during the outbreak period (April to September, 1997). Only three (19%) of the 16 children who died and none of the surviving children with AFP yielded enteroviruses in culture. One of the enteroviruses isolated from the serum of child who died was typed as echovirus type 25 (Chan Kwai Peng, Singapore General Hospital, personal communication), whereas the other two had EV71 (serum and rectal swab in one patient and throat swab in the other).

Other viruses isolated from fatal-case samples were dengue virus (type 3) from cerebrospinal fluid and herpes simplex virus type 2 from mouth-ulcer swab. One patient was flavivirus positive in cerebrospinal fluid by RT-PCR, although we did not isolate in culture a flavivirus or any other agent from this patient. All patients tested negative for IgM to Japanese encephalitis and dengue viruses.

Cytopathic effect was seen in long-passage material from A549 cells inoculated with samples in 15 patients: ten (63%) of 16 children who died and five (63%) of eight surviving children with AFP. The identification of this agent was difficult because it was hard to grow in sufficient



Figure 1: Alignment of forward and reverse primer priming sites. Mismatches to Allard primer sequences⁴ are boxed. Genbank accession numbers: Ad2, J01917; Ad3, X76549; Ad4, AF065064; Ad12, X73487; Ad41, D13781.

amounts for standard neutralisation assays. We have called it "agent Y" because a still unidentified agent isolated by CDC scientists from specimens obtained from the same patient group has been designated "agent X" (unpublished CDC reports to the Ministry of Health, Government of Malaysia). Samples from all the AFP cases had also been submitted to the poliovirus surveillance laboratory at the Institute for Medical Research in Kuala Lumpur, but no poliovirus or other enterovirus infection was reported for any of these children.

At least six of eight agent Y isolates tested by immunofluorescence were weakly positive for adenoviruses, but confirmation by PCR was initially negative. Stringency of the PCR conditions was reduced by lowering the annealing temperature from 54°C to 50°C and increasing the number of cycles from 40 to 45. PCR product was initially obtained in this manner for three agent Y isolates and these products were cloned and sequenced. A BLAST search of the GenBank sequence database (NCBI, Bethesda, MD, USA) showed that these agent Y isolates were 92% homologous with adenovirus type 16 in this region of the *hexon* gene. Interestingly, the sequence of the PCR product from an untypable adenovirus isolated from the cerebrospinal fluid and stool samples of a child with AFP (aged 13 months) from Singapore was found to be almost identical to that of the adenoviruses isolated from children in Sibul. This adenovirus was neutralised by antisera to adenovirus types 11, 34, and 35. EV71 was also isolated from stool samples but not cerebrospinal fluid from this patient (Chan Kwai Peng, Singapore General Hospital, Singapore, personal communication). The sequences of representative PCR products have been deposited with the European Molecular Biology Laboratory (Hinxton, Cambridge, UK) and have accession numbers AJ005423, AJ011574, and AJ011575.

We obtained the complete sequence of the *hexon* gene from the first of our agent Y isolates from the tenth child who died, which we have designated SIBU97 (accession number AJ012091). We submitted this sequence to a BLAST search of GenBank and the best three matches returned were the subgenus B adenoviruses type 7 (87% homology), type 3 (86% homology), and type 16 (83% homology).

The primers initially used to detect adenovirus genome in the agent Y cultures⁴ were compared with the *hexon* sequence of SIBU97 and found to have multiple mismatches in the priming sites for both primers (three of 25 in the forward primer and five of 23 in the reverse primer). The alignment of the priming sites in

Patient	Age (months)	Sex	Date*		Presentation and echocardiography	Viral prodrome†	CSF analysis	Specimens on admission	Necropsy samples‡	Histopathological examination	Virus (specimen)
			Presented	Died							
1	19	Male	Apr 14	Apr 15	Shock, respiratory failure, PCGLV	Yes, no HFM lesions	No CSF	None	None
2	9	Female	Apr 20	Apr 21	Possible seizure, RUL AFP, cardiopulmonary failure 10 h after admission, PCGLV	Yes, no HFM lesions	CSF split	None	None
3	6	Male	Apr 23	Apr 23	Cardiopulmonary failure/arrest in ER, PCGLV	Yes, no HFM lesions	No CSF	None	None
4	34	Female	May 4	May 4	Headaches, vomiting, clouded sensorium, cardiovascular collapse 1 h after admission, PCGLV	Yes, no HFM lesions	ASM	Serum, CSF	None	..	No growth
5	8	Female	May 5	May 6	RUL AFP, right ptosis, shock, PCGLV	Yes, macular rash on lower limbs	ASM	Serum, CSF	None	..	No growth, RT-PCR possible for flavivirus from CSF
6	44	Female	May 8	May 8	Cardiopulmonary failure, ventricular arrhythmias, PCGLV	Yes, no HFM lesions	No CSF	Serum	None	..	Agent Y
7	22	Female	May 14	May 14	Vomiting, seizure, shock, PCGLV	Yes, mouth ulcers	No CSF	Serum	None	..	Echovirus 25 and agent Y (Ad by nested PCR) from serum
8	15	Male	May 25	May 28	Cardiopulmonary failure, PCGLV	Yes, no HFM lesions	No CSF	None	None
9	19	Male	May 28	May 28	Shock, PCGLV (video recording available)§	Yes, HFM	No CSF	Serum, RS, TS	None	..	EV71 from serum, RS, agent Y (SIBU97) from serum
10	5	Male	..	May 29	Brought in dead	Yes, no HFM lesions	No CSF	..	Serum, CSF, TS, RS	..	Agent Y (SIBU97) from CSF, characterised as subgenus B adenovirus
11	10	Male	May 29	May 30	Seizures, cardiopulmonary failure 10 h after admission, PCGLV	Yes, HFM	ASM	Serum, CSF, TS, RS	None	..	EV (not typed) from serum, agent Y from TS
12	53	Male	May 1	May 1	Shock, PCGLV	Yes, HFM	..	Serum, CSF, TS, RS	None	..	Agent Y from TS
13	8	Male	..	June 1	Brought in dead	Yes, no HFM lesions, escar on buttock	Serum, CSF, TS, RS	..	Dengue 3 in CSF, agent Y (SIBU97) from TS, CSF
14	22	Female	June 5	June 5	Seizure, cardiopulmonary arrest witnessed by primary-care physician, brought in dead	Yes, HFM	Normal	..	Intracardiac blood, CSF TS, RS	..	No growth
15	18	Female	June 9	June 10	Drowsy, lethargy, shock 16 h after admission, PCGLV	Yes, HFM	ASM	Serum, CSF	Cardiac muscle biopsy	Cardiac muscle normal	Agent Y (Ad by IF) from cardiac muscle, agent Y (Ad by IF) from CSF of sibling survivor
16	22	Male	June 10	June 11	Acute cardiovascular collapse, PCGLV	Yes, HFM	ASM	Serum, CSF	Intracardiac blood, cardiac muscle biopsy	Cardiac muscle normal	No growth, IgG and seroconversion shown against SIBU97
17	22	Male	June 11	June 13	Lethargy, shock, LVEF 30% at admission, ventricular dysrhythmias before death	Yes, HFM	ASM	Serum, CSF	Cardiac muscle biopsy; liver biopsy	Cardiac muscle, liver normal	No growth
18	27	Male	June 23	June 24	Vomiting, acute cardiopulmonary failure 6 h after admission, PCGLV	Yes, HFM	ASM	Serum, CSF, RS, TS	Liver, lung, spleen, adrenals, brain, heart, kidney	ASM and encephalitis, normal heart, lung congestion and oedema	Agent Y (Ad by PCR) from brain, heart, and lung
19	7	Female	June 23	June 28	Acute cardiopulmonary failure/arrest, PCGLV	Yes, no HFM lesions	ASM	Serum, CSF, RS, TS	Brain, heart, liver biopsy	Normal myocardium, focal hepatic necrosis, vascular congestion in brain	No growth
20	33	Male	June 29	June 29	Shock, PCGLV	Yes, mouth ulcers, macular rash on buttocks/right palm	ASM	Serum, CSF, mouth ulcer swab, RS, TS	Heart, liver biopsy	Normal cardiac and liver tissue	HSV-2 from mouth ulcer, agent Y (SIBU97) from CSF and heart; sibling had EV71 HFM

Ad=adenovirus; ASM=aseptic meningitis; CSF=cerebrospinal fluid; ER=emergency room; HFM=hand, foot, and mouth disease; HSV=herpes simplex virus; IF=immunofluorescence; LVEF=left ventricular ejection fraction; PCGLV=poorly contractile globular left ventricle; RS=rectal swab; RUL=right upper limb; RT-PCR=reverse-transcriptase PCR; TS=throat swab. *All 1997. †When it was apparent that there was a large outbreak of HFM in the community, children with rash on the extremities or mouth ulcers were clinically diagnosed as having HFM. ‡Consent for full necropsy was given for only one patient (18); tissue samples obtained from some other patients were throughout biopsies. §Available from *Lancet* website (www.thelancet.com).

Table 1: **Fatal cases**

representative adenovirus serotypes indicates that these primers are unsuitable for use with other subgenus B adenoviruses (figure 1).

To improve detection of this fastidious adenovirus in agent Y cultures, we synthesised primers for nested PCR based on the sequence we obtained for SIBU97. The outer

Patient	Age (months)	Sex	Date* presented	Presentation	Viral prodrome	CSF analysis	Samples on admission	Outcome	Virus (specimen)
1	12	Female	May 2	Acute diarrhoea, RLL AFP	Yes, no HFM lesions	ASM	Serum, CSF	Discharge with residual deficit	Agent Y (SIBU97) from serum
2	8	Male	May 4	LUL AFP	Yes, no HFM lesions	ASM	Serum, CSF	Discharge with residual deficit	Agent Y (SIBU97) from serum
3	11	Male	June 24	Generalised tonic-clonic seizure, RUL monoparesis	Yes, no HFM lesions	ASM	Serum, TS, RS, CSF	Discharge with residual deficit	No growth
4	9	Female	June 26	LUL AFP	Yes, HFM lesions	ASM	Serum, TS, mouth ulcer swab	Discharge with residual deficit	No growth
5	14	Male	June 27	Vomiting and lethargy, developed LLL AFP	Yes, HFM lesions	ASM	Serum, TS, RS, CSF	Discharge with residual deficit	Ad 12 from TS, RS and CSF, agent Y from CSF only
6	19	Male	July 2	Flaccid paralysis of both lower limbs	Yes, no HFM lesions	ASM	Serum, TS, RS, CSF	..	Agent Y from CSF
7	14	Female	July 11	Altered sensorium, AFP of both lower limbs, unstable CVS	Yes, HFM lesions	ASM	Serum, TS, RS, CSF, stool	Discharge with improved power	Agent Y (Ad by IF) from stool, CSF
8	4	Male	August 11	Lethargy, vomiting, altered sensorium, LUL monoparesis, poor swallowing, weak gag	Yes, mouth ulcers, macular rash on arms and soles of feet	ASM	Serum, TS, RS	Discharge with improved power	No growth

Ad=adenovirus; ASM=aseptic meningitis; CSF=cerebrospinal fluid; CVS=cardiovascular system; IF=immunofluorescence; LLL=left lower limb; LUL=left upper limb; RLL=right lower limb; RUL=right upper limb; TS=throat swab. *All 1997.

Table 2: Non-fatal AFP cases

primer set was 5'-AACATGACCAAGACTGGTT-3' (forward) and 5'-GCCGAGAAGGGCGTGCGCAGGTA-3' (reverse), and the inner primer set was 5'-TTCAGAACTTCCAGCCCATGAG-3' (forward) and 5'-TCCATGGGATCCACCTCAAAGTCAT-3' (reverse). The cycling conditions were 94°C for 5 min, 30 cycles of 94°C for 45 s, 55°C for 45 s, 72°C for 45 s, with a final extension at 72°C for 5 min. For the second (nested) PCR, the annealing temperature was raised to 60°C, giving a 349 bp product. We applied this nested PCR to other agent Y cultures and the cumulative results of virus isolation and identification are shown in tables 1 and 2.

Ten of 15 patients with agent Y isolates were positive for adenovirus by immunofluorescence or PCR, or nested PCR. The remaining, as yet unidentified, agents isolated from A549 cells have the same growth characteristics and cytopathic effect in A549 cells as those we identified as adenoviruses, but we have no formal evidence that all these agents are the same.

Table 3 shows the sites that yielded proven enteroviruses and adenoviruses from patients who died. Four enteroviruses and 11 adenoviruses were isolated (some viruses were isolated from multiple sites). Two of four enteroviruses and ten of 11 adenoviruses were isolated from sterile sites.

In those patients with fatal disease, a third had dual infections. Of those from whom any virus isolates were obtained, half had dual infections. Every child from whom we isolated an enterovirus and who died from the disease also had agent Y or adenovirus.

Since the poor growth of the adenovirus isolates made it difficult to do standard virus neutralisation assays for serotyping, we amplified part of the VA RNA gene using primers described previously⁹ and obtained a PCR product

Site of isolation	Enterovirus	Adenovirus
Serum	2 (EV71, echovirus 25)	2
Cerebrospinal fluid	0	3
Throat swab	1	1
Rectal swab	1 (EV71)	0
Cardiac muscle	0	3
Brain	0	1
Lung	0	1
Total	4	11

Table 3: Sites of isolation of enteroviruses and adenoviruses from fatal cases

of approximately 500 bp, consistent with a subgenus B1 adenovirus. We used the restriction enzyme *TaqI* to obtain a restriction profile of the PCR product (figure 2) and compared it with published profiles⁹ to identify the serotype, but no match was made. The *TaqI* restriction profile obtained from the VA RNA gene PCR product of this virus does not match any of the adenovirus subgenus B prototypes (A Kidd, Umea University, Umea, Sweden, and J de Jong, Erasmus University, Rotterdam, Netherlands, personal communication) and at this stage we have identified SIBU97 to be a subgenus B1 adenovirus, which was also confirmed by the Centers for Disease Control and Prevention (M Pallansch, CDC, Atlanta, GA, USA, personal communication).

Discussion

The deaths of children during a hand, foot, and mouth disease outbreak in Sarawak have raised many questions about this familiar seasonal infection. The deaths were remarkable for their rapidity of onset characterised by severely depressed myocardial contractility on echocardiography and progressive refractory cardiac dysfunction. These deaths, coupled with the observation of associated neurological signs, including seizures, aseptic

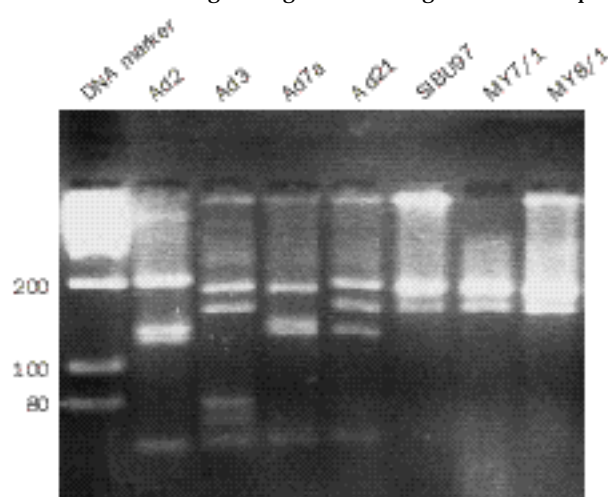


Figure 2: *TaqI* restriction digest profile of VA RNA gene PCR product

All adenoviruses shown are clinical isolates, except Ad21, which was obtained from the American Type Culture Collection.

meningitis, and flaccid limb monoplegias in most of these children, gave rise to initial suspicions of a large-scale enterovirus outbreak.

The isolation of EV71 from some of the children who died has raised speculation on whether infection with this virus is the cause of death. This assumption has been further strengthened by necropsy findings of significant brain-stem encephalitis, especially since myocardial tissue samples consistently appear normal on light-microscopy examinations (J Dolkadir, Central Medical Laboratory, Sarawak, personal communication). The clinicopathological discordance has led some investigators to believe that neurogenic mechanisms, specifically neurogenic pulmonary oedema,¹⁰⁻¹² are the cause of the cardiovascular manifestations. However, such explanations, which suggest that the heart was secondarily affected after a primary enteroviral infection of the central nervous system, do not convincingly explain the finding of severely depressed myocardial function (the hallmark of this syndrome). Indeed, we suggest that although infection of the central nervous system is an integral feature, primary myocardial dysfunction is the cause of death.

In the children who died in Sibü, enteroviruses were isolated from only three of 16, and none of the isolates were from tissue-specific sites that would have increased their clinical importance. The finding that EV71 isolates from clinically similar cases during the EV71 hand, foot, and mouth disease season in Taiwan are genetically distinct from the Sarawak isolates³ further diminishes the possibility that EV71 is the agent responsible for both these unusual outbreaks. However, we isolated a fastidious agent from A549 cells from various sterile tissue sites in several children who died and subsequently showed this to be subgenus B adenovirus. This finding has considerable implications.

Apart from enteroviruses,¹³ adenoviruses are now also suggested to be important causal agents of myocarditis. Martin and co-workers¹⁴ have shown that adenoviral myocarditis is often associated with histopathologically normal cardiac tissue, which is consistent with our findings. Massive ultrastructural damage of myocardial tissue, mediated by direct viral tissue invasion, or possibly viral toxins¹⁵ or viral-induced cytokines,^{16,17} probably results in the severe cardiac dysfunction seen in our patients.

More remarkable, however, is the isolation of this agent from cerebrospinal fluid samples from children with AFP. Surprisingly, intense efforts to isolate enteroviruses from children who died and children with AFP were unsuccessful. This contrasts with the high rate of isolation of enteroviruses (mainly EV71, also Coxsackie A16 virus and echoviruses) in children with uncomplicated hand, foot, and mouth disease. In view of recent findings by Solomon and colleagues,¹⁸ who linked AFP to Japanese encephalitis virus in Vietnam, we seem to have only a basic knowledge of the aetiologies of some of the viral syndromes prevalent in southeast Asia.

We are therefore confronted with a fastidious, subgenus B adenovirus that can infect tissues of the central nervous system and heart. Isolated infections of the central nervous system probably result in non-fatal AFP. Concurrent myocardial infection probably results in myocardial failure and death. Dual infection with this adenovirus and EV71

and the temporal association of the deaths with an EV71-related hand, foot, and mouth disease season indicate that these agents may interact.

Contributors

See Chang Wong and Shekhar Krishnan managed patients and collected clinical data and samples at Sibü Hospital. Jane Cardosa and Phaik Hooi Tio processed specimens, and isolated and identified viruses. Jane Cardosa and David Perera did the molecular biology. The analysis and writing was done by See Chang Wong, Shekhar Krishnan, and Jane Cardosa. All investigators contributed to the preparation of the paper.

Acknowledgments

We thank the dedicated team of nurses and technicians who packed and transported specimens during the outbreak; Mohamad Taha Arif (director of the Sarawak Health Department) and Tan Sri Abu Bakar Sulaiman (Director General of Health, Government of Malaysia) for support, encouragement, and permission to publish the findings; Mark Pallansch (CDC, Atlanta, GA, USA) for generously sharing primers; and Zawawi Ismail, Ghazally Ismail, Andrew Kiyu, Yao Sik King, and Abdul Rahim Abdullah for providing unstinting moral support in a time fraught with tension and exhaustion.

The work was supported partly by operational funds from the Universiti Malaysia Sarawak and the Sarawak Health Department and partly by a grant from the State Government of Sarawak, Malaysia.

References

- 1 WHO. Outbreak of fatal myocarditis in Sarawak. *Wkly Epidemiol Rec* 1997; **72**: 184.
- 2 WHO. Outbreak of hand, foot and mouth disease in Sarawak. *Wkly Epidemiol Rec* 1997; **72**: 211.
- 3 CDC. Deaths among children during an outbreak of hand, foot and mouth disease—Taiwan, Republic of China, April–July 1998. *MMWR Morb Mortal Wkly Rep* 1998; **47**: 629–32.
- 4 Allard A, Girones R, Juto P, Wadell G. Polymerase chain reaction for detection of adenoviruses in stool samples. *J Clin Microbiol* 1990; **28**: 2659–67.
- 5 Romero JR, Rotbart HA. PCR detection of the human enteroviruses. In: Persing, DH, Smith TF, Tenover FC, White TJ, eds. *Diagnostic molecular microbiology: principles and applications*. Washington, DC: American Society for Microbiology, 1993: 401–06.
- 6 Tanaka M. Rapid identification of flavivirus using the polymerase chain reaction. *J Virol Methods* 1993; **41**: 311–22.
- 7 Cardosa MJ, Fazeha B, Sharifah H, Tio PH, Nimmannitya S. A nitrocellulose membrane based IgM capture enzyme immunoassay for etiological diagnosis of dengue virus infections. *Clin Diagn Virol* 1995; **3**: 343–50.
- 8 Solomon T, Thao LT, Dung NM, et al. Rapid diagnosis of Japanese encephalitis by using an immunoglobulin M dot enzyme immunoassay. *J Clin Microbiol* 1998; **36**: 2030–34.
- 9 Kidd AH, Jonsson M, Garwicz D, et al. Rapid subgenus identification of human adenovirus isolates by a general PCR. *J Clin Microbiol* 1996; **34**: 622–27.
- 10 Chang L-Y, Huang Y-C, Lin T-Y. Fulminant neurogenic pulmonary oedema with hand, foot and mouth disease. *Lancet* 1998; **352**: 367–68.
- 11 Lum LCS, Wong KT, Lam SK, Chua KB, Goh AYT. Neurogenic pulmonary oedema and enterovirus 71 encephalomyelitis. *Lancet* 1998; **352**: 1391.
- 12 Lum LCS, Wong KT, Lam SK, et al. Fatal enterovirus 71 encephalomyelitis. *J Pediatr* 1998; **133**: 795–98.
- 13 Bowles NE, Richardson PJ, Olsen EGJ, Archard LC. Detection of Coxsackie B virus specific RNA sequences in myocardial biopsy samples from patients with myocarditis and dilated cardiomyopathy. *Lancet* 1986; **i**: 1120–23.
- 14 Martin AB, Webber S, Fricker FJ, et al. Acute myocarditis: rapid diagnosis by PCR in children. *Circulation* 1994; **90**: 330–39.
- 15 Brandon FB, McClean IWM Jr. Adenovirus. *Adv Virus Res* 1962; **9**: 157–93.
- 16 Yokoyama T, Vaca L, Rossen RD, Durante W, Hazarika P, Mann DL. Cellular basis for the negative inotropic effects of tumor necrosis factor-alpha in the adult mammalian heart. *J Clin Invest* 1993; **92**: 2303–12.
- 17 Libby P, Mitchell RN. Cytokines score a knockout: harnessing gene targeting to gain insight into the pathogenesis of myocarditis. *Circulation* 1997; **95**: 551–52.
- 18 Solomon T, Kneen R, Nguyen MD, et al. Poliomyelitis-like illness due to Japanese encephalitis virus. *Lancet* 1998; **351**: 1094–97.