

EDUCATION

MJPCH Vol. 28 (2) December 2022

OFFICIAL JOURNAL



IS IT REALLY ANOTHER FOREIGN BODY?

Lim Li Yun ^{1,2}, Shamina Sara Moses²

Keywords: Cholesteatoma, congenital, child
DOI: 10.51407/mjpch.v28i2.208

Received: 26 August 2021; **Accepted revised manuscript:** 08 June 2022; **Published online:** 05 December 2022

Case summary

A 4-year-old boy was referred to our ENT clinic for foreign body (white bead) in the right ear. The white bead was removed successfully without much struggle from the boy. However, the repeated otoscope was done and the findings was seen in Figure 1. Further history taking, the boy did not have any frequent ear infections or problems. His pure tone audiometry showed normal hearing bilaterally.

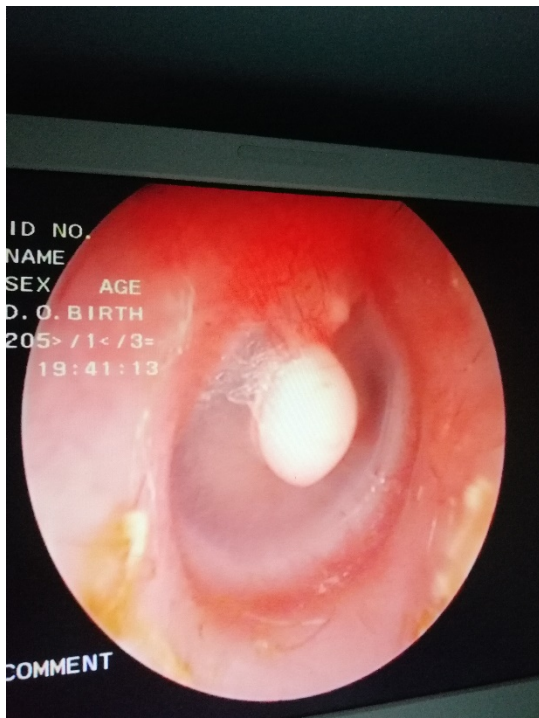


Figure 1. The otoscopy finding of right tympanic membrane. There was a white “pearl-like” mass attached to the intact tympanic membrane. The tympanic membrane did not look inflamed and the surrounding mucosa looks healthy.

Do you know the diagnosis?

Answer:

This is a congenital cholesteatoma of the right tympanic membrane. The otoscope finding shows presence of a single, pearl-like lesion centred on the tympanic membrane, arising from the middle ear, abutting the manubrium of the malleus.

Discussion

Congenital cholesteatoma is defined when there is no prior surgery or injury to the ear [1]. As most cholesteatoma arise from the middle ear or mastoid cavity, intratympanic occurrence of congenital cholesteatoma is extremely rare [2]. In a recent systematic analysis, 1/3 of cases of congenital cholesteatoma were asymptomatic and incidentally noted during routine otoscopy examination [3].

The appearance of the lesion is quite similar to that of a foreign body ear; which may be easily mistaken or missed as in the above patient. The discerning factor in distinguishing a congenital cholesteatoma of the tympanic membrane from a foreign body ear; is the appearance of a healthy-looking, and non-inflamed tympanic membrane despite presence of a lesion. This condition may or may not be associated with the recurrent ear infections or history of ear

¹Otorhinolaryngology Head and Neck Department, Faculty of Medicine and Health Sciences, Universiti Malaysia Sarawak, 94300 Kota Samarahan, Sarawak, Malaysia

²Department of Otorhinolaryngology, Head and Neck Surgery, Sarawak General Hospital, Jalan Hospital 93586, Sarawak, Malaysia

Corresponding Author:

Lim Li Yun, Otorhinolaryngology Head and Neck Department, Faculty of Medicine and Health Sciences, Universiti Malaysia Sarawak, 94300 Kota Samarahan, Sarawak, Malaysia

Tel: 082-581000 **Email:** lylim@unimas.my

surgery.

The differential diagnosis of a whitish mass behind an intact tympanic membrane includes tympanosclerosis, cartilage grafting post ear surgery or middle ear tumours such as osteoma. In tympanosclerosis or tympanic membrane scarring, the lesion is depicted as a chalky whitish-patch, with its irregular edges spreading throughout the tympanic membrane. Previous history of ear surgery may provide the clue towards scarring or grafting.

Imaging modalities such as Computed Tomography (CT) is essential and necessary for surgical planning, according to a consensus study achieved by International Pediatric Otorhinolaryngology Group, despite some authors belief that the under-developed mastoid in children may limit its role in identifying cholesteatoma [4]. Even though, Magnetic Resonance Imaging (MRI) is superior compared to CT in delineating the extent of cholesteatoma, MRI in children requires a longer scanning time and usually general anaesthesia. Therefore, CT is advantageous in overcoming the above limitations and MRI is only recommended cases deemed necessary [4].

The usage of topical antibiotic ear drop is not advisable if there is no sign of ear infection. Surgery remains as the first line treatment in cholesteatoma, be it congenital or acquired. The main aim of surgery is to eradicate the disease, provide a safe and dry ear and subsequently restore hearing [5]. The earlier the removal of lesion, the lesser the chances of it invading into the middle ear. In our index case, transaural endoscopic tympanoplasty, would be the management of choice which would involve peeling off the lesion from the tympanic membrane and placing a graft over the defect if needed. Complications of untreated congenital cholesteatoma include facial nerve paralysis, hearing impairment and vertigo due to presence of labyrinthine fistula [5].

Conclusion

Congenital cholesteatoma may not be a common ear problem, however it is important for any medical personnel to be able to identify and diagnosed it. Early detection and intervention will prevent unnecessary complications.

References

- [1] Derlacki EL, Clemis JD. LX Congenital Cholesteatoma of the Middle Ear and Mastoid. *Annals of Otology, Rhinology & Laryngology*. 1965;74:706-27.
- [2] Reddy CE, Goodyear P, Ghosh S, Lesser T. Intratympanic membrane cholesteatoma: a rare incidental finding. *European Archives of Oto-Rhino-Laryngology and Head & Neck*. 2006;263:1061-4.
- [3] Gilberto N, Custódio S, Colaço T, Santos R, Sousa P, Escada P. Middle ear congenital cholesteatoma: systematic review, meta-analysis and insights on its pathogenesis. *European Archives of Oto-Rhino-Laryngology*. 2020;277:987-98.
- [4] Denoyelle F, Simon F, Chang KW, Chan KH, Cheng AG, Cheng AT, et al. International Pediatric Otolaryngology Group (IPOG) consensus recommendations: congenital cholesteatoma. *Otology & Neurotology*. 2020;41:345-51.
- [5] Goh BS, Faizah AR, Salina H, Asma A, Saim L. Congenital Cholesteatoma: delayed diagnosis and its consequences. *Med J Malaysia*. 2010;65:189.