

ABSTRACT

POSTER PRESENTATIONS

Advances in Pain Management

Buffered dextrose 5% – an alternative analgesia

M. L. Swee¹, H. E. Liu¹, Y. Y. Jasmine Sze¹, H. N. Kooi¹, H. C. Siew¹, S. Shantene¹, M. Nadiah¹, M. Asmah¹, C. G. Suk¹

¹Hospital Tuanku Ja'afar Seremban, Seremban, Malaysia

Background/Purpose: Chronic pain around neck and upper limbs (NUL) among patients with rheumatic and musculoskeletal disease (RMD) is challenging to handle. Dr John Lyftogt has established the use of buffered dextrose 5% with pH of 7.4 (BD5%) in Perineural injection therapy (PIT) to treat such condition with success.

Our primary objective is to assess pain score reduction (PSR) in Numerical Rating scale (NRS) after PIT in this region. Secondary objective is to assess percentage of patients who achieved at least 50% PSR at the end of treatment.

Methods: Patients with NUL pain who received PIT in 2019 and had followed up for 12 months were reviewed. PIT was performed by serial injection of BD5% along the superficial nerve(s) underneath the skin using 30G, 1cm hypodermic needle. Patients with pain score not recorded or still undergoing PIT were excluded. PSR before and after series of treatments were analysed using paired T test.

Results: 21 patients with NUL pain were treated with total of 61 PIT. Mean age was 58.1. 76.2% (n = 16) were female. 57.1% (n = 12) had shoulder tendinopathy with or without tear, 33.3% (n = 7) had fibromyalgia while 9.5% (n = 2) had cervical spondylosis.

Baseline pain score was 7.0 ± 1.4 , duration of pain was 1.8 ± 1.6 years. Average 2.9 ± 1.5 times of PIT were performed. 19% (n = 4) had one PIT, 23% (n = 5) needed two while 29% (n = 6) needed three PIT. Distribution of cases according to number of PIT as shown in Figure 1.

Pain score reduced to 2.9 ± 1.7 , 2.1 ± 1.4 and subsequently 1.4 ± 1.1 following first, second and third PIT. On average, PSR was 6.0 ± 2.2 (p = 0.0001). The effect lasted for 5.7 ± 4.2 months. No complications were observed.

100% of them demonstrated 50% or more PSR.

Conclusion: Buffered dextrose 5% in perineural injection therapy alleviates NUL pain significantly. This is a good and safe alternative treatment for RMD patients with NUL pain.

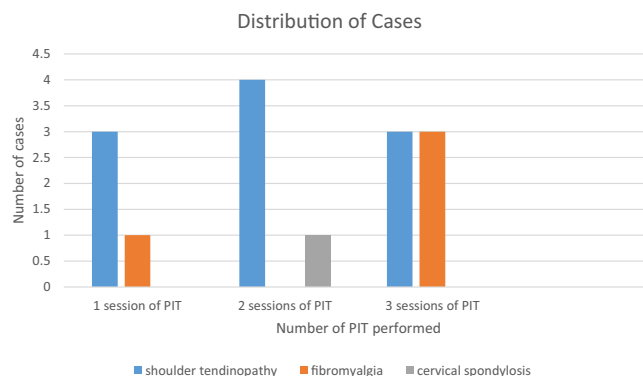


FIGURE 1 Distribution of cases according to number of PIT needed

Buffered dextrose 5% - the sweet solution for chronic low back pain

M. L. Swee¹, S. Shantene¹, H. E. Liu¹, Y. Y. Jasmine Sze¹, H. N. Kooi¹, H. C. Siew¹, M. Nadiah¹, M. Asmah¹, C. G. Suk¹

¹Hospital Tuanku Ja'afar Seremban, Seremban, Malaysia

Background/Purpose: Chronic low back pain (CLBP) is one of the constant struggle among patients with rheumatic and musculoskeletal disease (RMD). Dr John Lyftogt had used buffered dextrose 5% with pH of 7.4 (BD5%) via caudal epidural injection (CEI) to treat CLBP successfully.

Our primary objective is to assess pain score reduction (PSR) in Numerical Rating scale (NRS) after CEI. Secondary objective is to assess percentage of patients who achieved at least 50% PSR at the end of treatment.

Methods: Patients with CLBP who received CEI in 2019 and had followed up for 12 months were reviewed. CEI was performed by giving 10 mL of BD5% at caudal epidural region via 26G, 1cm needle. Patients with pain score not recorded or still undergoing CEI were excluded. PSR before and after series of treatments were analysed using paired T test.

Results: 35 patients received total of 127 CEI for CLBP. Mean age was 62.1 years and 80% (n = 28) were females. 80% (n = 28) had mechanical low back pain due to spondylosis, prolapsed intervertebral disc, spinal stenosis and spondylolisthesis. 14.3% (n = 5) had



Fatal gastrointestinal manifestations of SLE: case reports

W. Lee Wan Hui¹, S. Benjamin¹, W. Sharifah Aishah¹, C. Yaw Kiet¹, D. Balakrishnan², J. Ahmad Tirmizi³, T. Cheng Lay¹

¹Rheumatology Unit, Department of Internal Medicine, Sarawak General Hospital, Kuching, Malaysia; ²Department of Radiology, Sarawak General Hospital, Kuching, Malaysia; ³Department of Radiology, Faculty of Medicine and Health Sciences, University Malaysia Sarawak, Kuching, Malaysia

Background: SLE-related gastrointestinal involvement such as gastrointestinal vasculitis and thrombosis are clinically important, as it could progress to life-threatening outcome if not treated promptly. We describe 2 patients who were admitted to our hospital with fatal gastrointestinal manifestations of SLE.

Method: Case Report.

Results: Case 1: The patient was a 24-year-old Asian woman who was diagnosed with SLE in 2014 and class IV lupus nephritis in 2018. She presented with hypovolemic shock secondary to massive hematochezia. CT abdomen and angiography revealed multiple bleeding sites in jejunum and mesenteric vasculitis changes of the bowels. Gastroduodenoscopy and CT angioembolization of the mesenteric arteries were performed to stop the bleeding, and IV Methylprednisolone, IV Cyclophosphamide, IV Rituximab were administered. Eventually she succumbed to Transfusion-Related Acute Lung Injury (TRALI) from multiple blood transfusions.

Case 2: The patient was a 61-year-old male smoker who was diagnosed with SLE with lupus nephritis in April 2020. He however refused renal biopsy or cyclophosphamide. He presented a few months later with fever and colicky abdominal pain for 2 days. A diagnosis of Superior Mesenteric Artery (SMA) Thrombosis with Bowel Ischemia was made, which was likely due to Catastrophic Anti-Phospholipid Syndrome (CAPS) with SLE, based on CT abdomen findings of SMA thrombosis, bilateral common femoral vein thrombosis and multiple splenic infarcts. Heparin infusion was initiated, and he was administered IV Methylprednisolone and Intravenous Immunoglobulin (IVIg). He developed Disseminated Intravascular Coagulation (DIC) subsequently and succumbed to his illness at day 2 of admission.

Conclusion: In summary, early diagnosis with prompt and adequate treatment of gastrointestinal manifestation of SLE is essential to avoid serious complications like haemorrhage or perforation with a high mortality rate.

Posterior reversible encephalopathy syndrome in patients with systemic lupus erythematosus following methylprednisolone pulse therapy

D. Marcos¹, M. Tee¹

¹Division of Rheumatology, Department of Medicine, University of the Philippines-Philippine General Hospital, Manila, Philippines

Background/Purpose: Methylprednisolone Pulse Therapy (MPPT) is one the treatment strategies used to control high disease activity of SLE. The occurrence of Posterior Reversible Encephalopathy (PRES) upon completion of MPPT regimen has been described in literature. The timing of onset of PRES has varied among different literature. Through this report, we aim to increase awareness that PRES can occur even after the 1st dose of MPPT.

Methods: Case Report

Results: We present 2 patients with active SLE who developed PRES after the first MPPT dose. The first patient is a 19-yo female diagnosed with SLE who presented with crampy abdominal pain for 1 week. Upon diagnostic evaluation, she was diagnosed to have mesenteric vasculitis and lupus nephritis. She was given 1 gm MPPT. Recurrent seizures were noted following the 1st MPPT dose. Electroencephalogram (EEG) and MRI studies showed hyperintense signals in the parietal, temporal and occipital lobes. The diagnosis of PRES was made. Our second patient is a 35-yo female patient with SLE who presented with generalized tonic clonic seizures upon admission. Following the first dose of MPPT, she sudden blurring of vision in the left eye which rapidly progressed to left monocular blindness. She was diagnosed to have PRES following the demonstration of hypodensities in the right parietal and bilateral temporal lobes on Contrast enhanced CT. Clinical recovery for both patients has been satisfactory following strict control of blood pressure and individualized immunosuppression regimens.

Conclusion: These 2 cases demonstrate the occurrence of PRES following MPPT as early as the 1st dose.

Clinical features and treatment outcome of neuropsychiatric lupus (NPSLE): a single centre experience

A. Masnammy¹, A. Bhullar¹, A. Mohamed Ismail¹, O. Seok Ling¹

¹Hospital Raja Perempuan Zainab II, Kota Bharu, Malaysia

Introduction: NPSLE encompasses neurologic and psychiatric manifestations involving the central (CNS) and peripheral nervous systems (PNS).

Objective: To identify patient characteristics, clinical features, SLEDAI, treatment protocol and outcome of patients with NPSLE.

Methodology: A retrospective, observational single centre study of all patients (n = 20) admitted for NSPLE from Dec 2017 to Dec 2019 in Hospital Raja Perempuan Zainab II. Neurological outcome was determined based on 3 and 6 months follow up .