

The Role of Ultrasonographic Biomicroscopy in the management of a patient with presumed Dematiaceous Mycotic Keratitis

A. K. Tan MD Department of Ophthalmology, Hospital Umum Sarawak Sarawak Malaysia

P. S. Premseenthil MS Department of Ophthalmology, Faculty of Medicine and Allied Health Science, Universiti Malaysia Sarawak (UNIMAS) Sarawak Malaysia

A. Aziz MS Department of Ophthalmology, Hospital Umum Sarawak Sarawak Malaysia

T. Asok MMed Department of Ophthalmology, Hospital Umum Sarawak Sarawak Malaysia

G. Intan MS Department of Ophthalmology, Hospital Umum Sarawak Sarawak Malaysia

Citation: A.K. Tan, P.S. Premseenthil, A. Aziz, T. Asok, G. Intan: The Role of Ultrasonographic Biomicroscopy in the management of a patient with presumed Dematiaceous Mycotic Keratitis. *The Internet Journal of Ophthalmology and Visual Science*. 2009 Volume 6 Number 2. DOI: 10.5580/d84

Abstract

We report the use of Ultrasonographic Biomicroscopy in the management of a patient with presumed dematiaceous mycotic keratitis.

Introduction

Keratomycosis is one of the leading causes of ocular morbidity ¹. Early diagnosis and treatment is necessary to ensure good visual outcome. Corneal scraping is routinely performed in cases of microbial keratitis. The initial stain results guide empirical therapy, while the culture and sensitivity results are of paramount importance. However, corneal scraping may not be possible in all situations. We describe a case where ultrasonographic biomicroscopy findings influenced the decision not to perform superficial keratectomy.

Case Report

A 38 year-old pregnant lady, who was in the 39th week of pregnancy, with a compromised left cornea due to herpetic keratitis, presented to our department with redness of the eye associated with photophobia of two weeks duration. There was no associated pain or discharge. She had no history of previous or recent ocular trauma and she was not a contact lens user.

She had developed herpetic keratitis in the left eye two months previously, which was treated with topical acyclovir ointment 3% w/w five times daily, resulting in resolution of the symptoms and formation of a central leukoma.

She had attended regular antenatal follow-ups and the pregnancy had been uneventful. Her children had all been delivered via spontaneous vaginal delivery (SVD) without complications. She has no past medical, surgical or drug history.

At presentation, her left eye visual acuity (VA) was hand movement (HM). The left eye was diffusely injected (Figure 1). There was a central leukoma measuring 5.4 mm horizontally and 5.0 mm vertically. At the centre of the leukoma was a depression measuring 1.6 mm horizontally and vertically. There was a brownish plaque covering the depression. The leukoma was superimposed by a full thickness stromal infiltrate. The edge of the stromal infiltrate was well defined and was not fluffy. There were no satellite lesions. The peripheral corneal stroma was oedematous, but iris detail was still visible. There was also peripheral corneal neovascularization. Corneal sensation was absent. Anterior chamber cells was 1+ and flare was 1+. There was a streak of hypopyon. Pupils were equal bilaterally and reactive to light. There was no relative afferent pupillary defect (RAPD). The intraocular pressure (IOP) measured with tonopen was 16 mm Hg. There was minimal eye discharge and the eyelids were not swollen. Her right eye was

normal with visual acuity (VA) of 20/20 and near vision of N6.

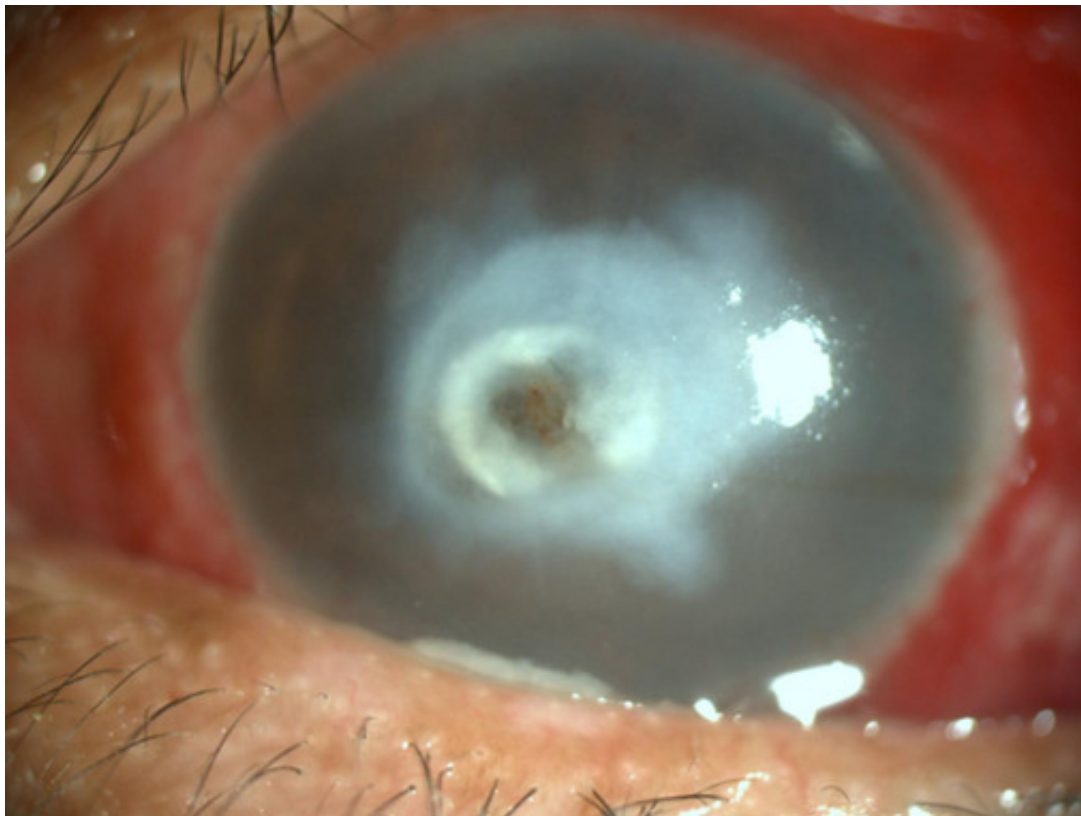

Figure 1: The patient's left eye at presentation.

A corneal scraping was performed around the edge of the depression, and the scraped material was sent for gram stain, Giemsa stain, KOH wet mount examination and Culture and Sensitivity (C&S). The scraping was not performed at the base of the depression in view of high risk of corneal perforation. Her initial medications were topical Ceftazidime (50mg/ml) 2 hourly, topical fortified gentamicin (14mg/ml) 2 hourly and topical acyclovir ointment 3% w/w 5 times daily. The clinical response after 48 hours was poor.

The presence of a brownish pigmented infiltrate raised the suspicion of dematiaceous fungal keratitis. We contemplated removing the central pigmented infiltrate for histopathological examination. Ultrasonographic biomicroscopy (UBM) (Sonomed VuMAX, Sonomed Inc., New York) was performed in order to determine the corneal thickness, the depth of the infiltrate and the possible risk of perforation during removal of the infiltrate. The grey scale display showed that the corneal thickness at the base of the infiltrate was only 0.37 millimetre. The depth of the pigmented infiltrate could not be determined with certainty (Figure 2).

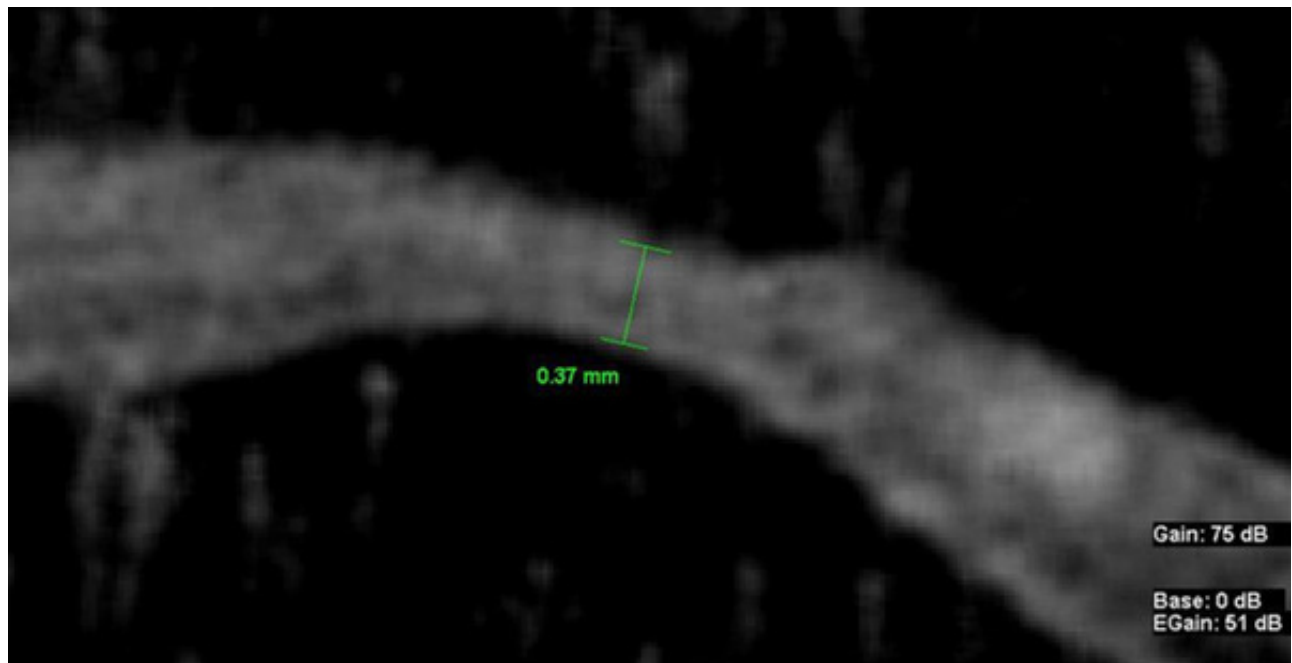


Figure 2: UBM grey scale display showing cross sectional view of the cornea.

The color scale display on the other hand showed that the pigmented infiltrate involve full-stromal thickness (Figure 3). The thinnest part of the cornea was coded green which indicated that the particular area was of moderate in density. It corresponded to the pigmented plaque in figure 1. Clearly, the green infiltrate encompassed the full stromal thickness. Hence, we concluded that the pigmented infiltrate involve full-stromal thickness. The risk of iatrogenic perforation due to removal of the pigmented infiltrate was very high. Therefore, it was decided not to perform the superficial keratectomy.

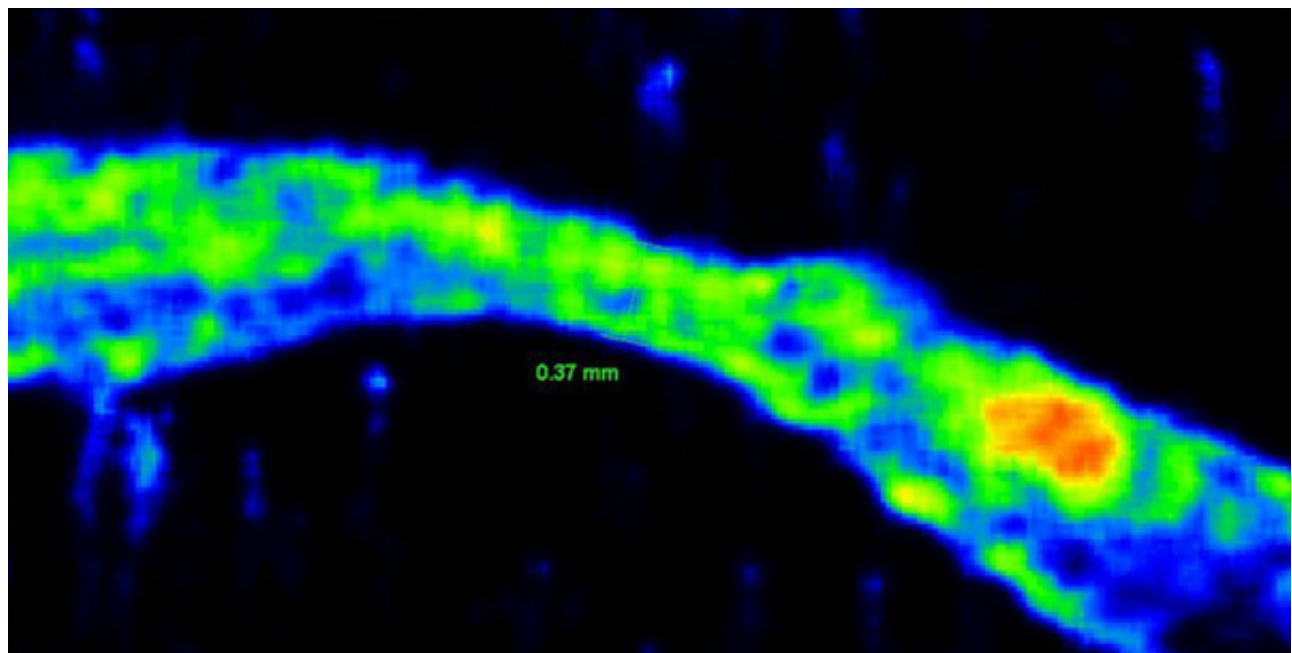


Figure 3: UBM color scale display showing cross sectional view of the cornea. The infiltrate involved full-stromal thickness.

A discussion was held with the obstetrician and the patient's husband regarding her ocular condition and the need to initiate antifungal therapy. She was subsequently admitted to the labour ward for induction of labour. She gave birth uneventfully the next day via SVD.

Antifungal therapy with oral Ketoconazole 200 mg daily, topical fluconazole 0.2% 2 hourly and topical amphotericin B 0.15% 2 hourly was initiated. She was also given oral Doxycycline 100 mg daily as an anti-collagenase. After 36 hours, the hypopyon disappeared. She improved symptomatically and the stromal infiltrate decreased.

The laboratory results were negative. There was neither fungal hyphae seen by direct microscopy nor bacteria seen by Gram stain. Culture failed to isolate any organism.

After 2 weeks on antifungal therapy, the stromal infiltrate resolved leaving the central leukoma behind. The vision of her left eye remained HM.

Discussion

Mycotic keratitis is a leading cause of ocular morbidity in Asia. The incidence of mycotic keratitis in tropical countries ranges from 44% 1 to 14% 2 . Major local predisposing factors for the development of mycotic keratitis include trauma, contact lenses and topical steroids. Other local risk factors include corneal surface disorders, dry eye, bullous keratopathy, exposure keratitis, post-photorefractive keratectomy and post-LASIK 3 . The cornea of our patient was compromised by corneal surface disorders due to herpetic keratitis.

Fungi involved in keratomycosis are classified by their morphology and by the presence or absence of pigment (table 1) 4 . *Fusarium* spp. and *Aspergillus* spp. are the major pathogens while Dematiaceous fungi are the cause of 8 to 16.7% cases of fungal keratitis 3 . Dematiaceous fungal keratitis characteristically presents with dry, raised, pigmented (black-brown), plaque-like infiltrate. The characteristic brown to black pigmentation on their cell walls of their vegetative cells or conidia results in pigmented colonies. There was a strong correlation of pigmentation with superficial location of fungal filaments and less severe inflammatory response 5 .

Yeast <i>Candida</i> spp.
Filamentous septated Nonpigmented hyphae (hyaline) <i>Fusarium</i> spp. <i>Aspergillus</i> spp. Pigmented hyphae (dematiaceous) <i>Alternaria</i> spp <i>Curvularia</i> spp.
Filamentous nonseptated <i>Mucor</i> spp

Table 1: Classification of Three Types of Fungi Involved in Keratomycosis

Garg et. al, reported that only 15% of culture proven dematiaceous fungal keratitis had the characteristic

plaque. The removed plaque had 100% smear positive and culture positive results. Histopathologically, there were heavy loads of fungal elements, assuming a carpet in the superficial layers of the cornea. Keratectomy was not without risk. 13% of cases had corneal perforation during keratectomy 5 . We averted this disastrous complication by performing UBM prior to keratectomy.

Dematiaceous keratomycosis generally have excellent prognosis. Treatment generally involve superficial keratectomy to reduce fungal load and intensive medical therapy with topical Natamycin 5% and oral Ketoconazole 200 mg twice daily 5 .

Prajna et. al, showed that there was no significant difference between topical Natamycin 5% and topical econazole 2% in terms of efficacy in fungal keratitis 6 . We believe this difference was due to class effect. As econazole and fluconazole belong to the Azole group of antifungal, we prescribed the more affordable topical fluconazole for our patient. Judging by the greater degree of inflammation and deeper corneal penetration, we added topical amphotericin B 0.15%.

Dense corneal opacities prevent the estimation of the depth of stromal infiltration. UBM provides valuable information in such situations. Estimation of the depth of stromal infiltrate prior to keratectomy further expands to role of UBM in our clinical practice.

Correspondence to

Dr. Tan Aik Kah, Trainee Lecturer, Ophthalmology unit, Faculty of Medicine and Health Sciences, University Malaysia Sarawak, Lot 77, Sekyzen 22 Kuching Town Land District, Jalan Tun Ahmad Zaidi Aduce, 93150 Kuching, Sarawak, Malaysia. Tel +6082 416550, Fax + 6082 422564, Email: portwinestain@hotmail.com aktan@fmhs.unimas.my

References

1. Sharma S, Srinivasan M, George C. The current status of Fusarium species in mycotic keratitis in South India. *J Med Microbiol* 1993;11:140-7.
2. Norina TJ, Raihan S, Bakiah S, et al. Microbial keratitis: aetiological diagnosis and clinical features in patients admitted to Hospital Universiti Sains Malaysia. *Singapore Med Jour* 2008;49(1):67-71.
3. Srinivasan M. Fungal keratitis. *Current Opinion in Ophthalmology* 2004;15:321-7.
4. Harissi-Dagher M, Colby K. Fungal Infections of the Cornea. *Contemporary Ophthalmology* 2006;5.
5. Garg P, Vemuganti GK, Chatarjee S, et al. Pigmented plaque presentation of dematiaceous fungal keratitis. A clinicopathological correlation. *Cornea* 2004;23(6):571-6.
6. Prajna N, John R, Nirmalan P. A randomised clinical trial comparing 2% econazole and 5% natamycin for the treatment of fungal keratitis. . *Br J Ophthalmol* 2003;87:1235-7.

Generated at: Sun, 02 Sep 2012 20:08:55 -0500 (00000d84) — <http://www.ispub.com:80/journal/the-internet-journal-of-ophthalmology-and-visual-science/volume-6-number-2/the-role-of-ultrasonographic-biomicroscopy-in-the-management-of-a-patient-with-presumed-dematiaceous-mycotic-keratitis.html>
