

## ETHAMBUTOL OCULAR TOXICITY IN A PATIENT WITH PULMONARY TUBERCULOSIS – A CASE REPORT

AK Tan MD<sup>1,2</sup>, PS Mallika MS<sup>2</sup>, S Aziz MS<sup>1</sup>, T Asok MMed<sup>1</sup>, G Intan MS<sup>1</sup>

<sup>1</sup>Department of Ophthalmology, Hospital Umum Sarawak, Sarawak, Malaysia (Tan Aik Kah, Mohamad Aziz Salowi, Asokumaran Thanaraj, Intan Gudom)

<sup>2</sup>Department of Ophthalmology, Faculty of Medicine and Allied Health Science, Universiti Malaysia Sarawak (UNIMAS), Sarawak, Malaysia (Tan Aik Kah, Mallika Premseenthil)

**Address for correspondence:** Dr. Tan Aik Kah, Lecturer, Ophthalmology unit, Faculty of Medicine and Health Sciences, University Malaysia Sarawak, Lot 77, Sekyzen 22 Kuching Town Land District, Jalan Tun Ahmad Zaidi Aduce, 93150 Kuching, Sarawak, Malaysia. Tel +6082 416550, Fax + 6082 422564, Email: portwinestain@hotmail.com, aktan@fmhs.unimas.my

### ABSTRACT

**Purpose.** To highlight the importance of using the Farnsworth Panel D-15 Hue test in colour vision testing in patients on ethambutol treatment.

**Case Report.** A 70 year-old lady received ethambutol as part of her anti-tuberculous regime. She developed blue-yellow colour defect detectable with the Farnsworth Panel D-15 Hue test, but not with the Ishihara Pseudoisochromatic Plates. Ethambutol was immediately discontinued from her anti-tuberculous regime. Two months later, her colour vision returned to normal.

**Conclusion.** This case report illustrates the importance of regular monitoring of patients receiving ethambutol for blue-yellow colour defect using the Farnsworth Panel D-15 Hue Test.

**Key Words:** Ethambutol, Farnsworth Panel D-15 Hue test, Ishihara Pseudoisochromatic Plates, Blue-yellow colour defect, Pulmonary tuberculosis.

*Tan AK, Mallika PS, Aziz S, Asok T, Intan G. Ethambutol ocular toxicity in a patient with pulmonary tuberculosis – a case report. Malaysian Family Physician. 2008;3(2):87-90*

### INTRODUCTION

Internists routinely prescribe drugs that can potentially cause ocular toxicity. Many non-ophthalmologists use Ishihara Pseudoisochromatic Plates (ISP) to screen for acquired colour defects. Such use of ISP is not appropriate. The Farnsworth Panel D-15 Hue test is rarely available outside the ophthalmology department. In this case report, we highlight the value of the Farnsworth Panel D-15 Hue test in the detection of acquired blue-yellow colour defect and advocate its use by non-ophthalmologists.

### CASE REPORT

A 70-year-old lady, diagnosed of having pulmonary tuberculosis (PTB), was started on EHRZ regime (ethambutol 15 mg/kg/day, isoniazid 5 mg/kg/day, rifampicin 10mg/kg/day and pyrazinamide 20 mg/kg/day). She was referred to our ophthalmology department 2 weeks after the treatment commenced. Her renal function was normal.

On presentation, she had mild blurring of vision for the past 10 years. Otherwise there were no acute visual symptoms. Her best corrected visual acuity (BCVA) was 6/12 in both eyes. Colour vision test with Ishihara Pseudoisochromatic Plates

(ISP) revealed no abnormality. However, Farnsworth Panel D-15 hue test (Figure 1) revealed asymmetrical tritanomaly (blue-yellow colour deficiency) (Figure 2).

The Farnsworth Panel D-15 hue test was performed in day light in front of a wide window. The caps are numbered from 1 to 15. A reference cap is fixed in the box on the patient's left side. The patient was first shown the normal order of the caps in the box. Then the caps were arranged in random order by the examiner. The test was performed first with the right eye. The patient was asked to rearrange the caps in normal order, step by step, starting from the reference cap. At the end of the test, the examiner closed the lid on the caps, turned the case up-side-down and opened it. The numbers of the caps will then appear. The numbers were reported on the score sheets in the order given by the patient. The test was repeated for the left eye. The result of the test can either be a "success" or a "failure". For this patient, her diagram formed criss-crossed lines according to tritan axis.

She also had mild posterior subcapsular cataract in both eyes. Dilated pupil fundus examination showed no abnormality in both eyes.

She was diagnosed to have bilateral acquired blue-yellow colour deficiency secondary to ethambutol-induced optic

neuropathy. She was immediately referred back to her chest physician in order to discontinue the offending anti-tuberculous medication. Two months after ethambutol discontinuation, a

repeat Farnsworth Panel D-15 hue test showed that her colour vision returned to normal (Figure 3).



Figure 1. Farnsworth Panel D-15 hue test equipment. Different colour caps put in the black square socket; reverse side of the socket with the discs showing the serial number from 1-15.

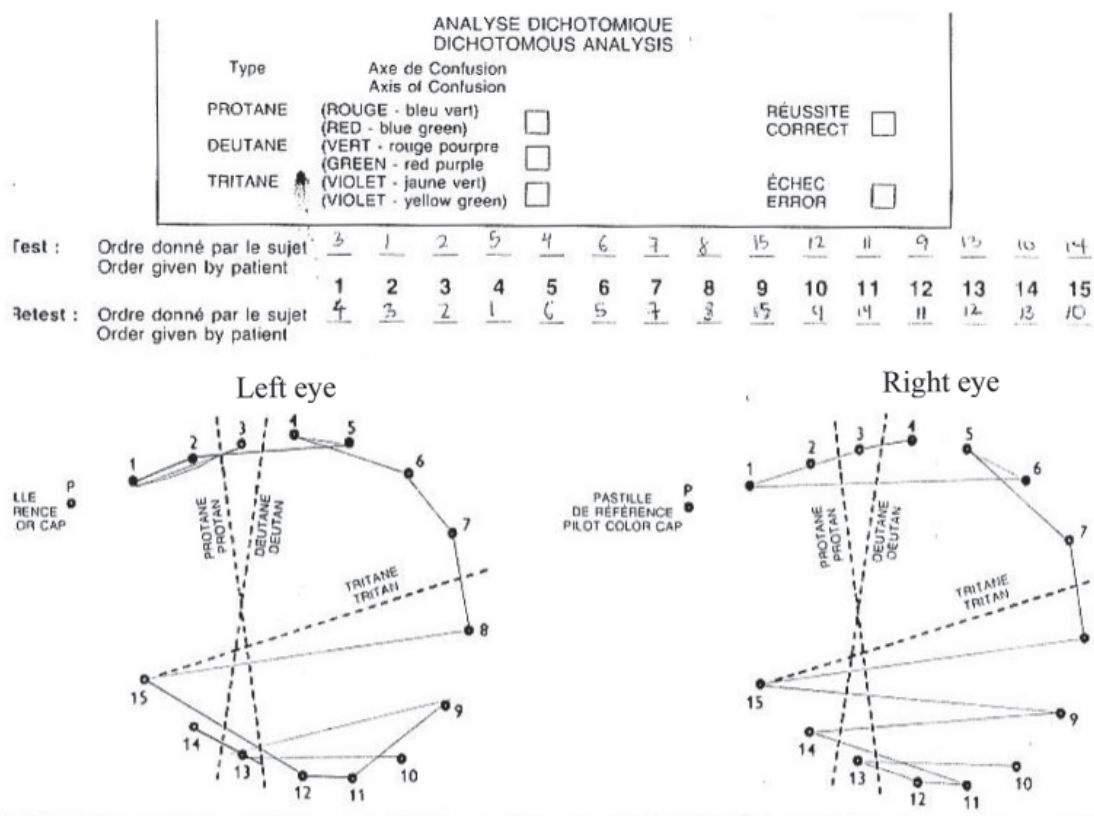


Figure 2. Farnsworth D-15 Hue Test at presentation showing bilateral asymmetrical tritanomaly.

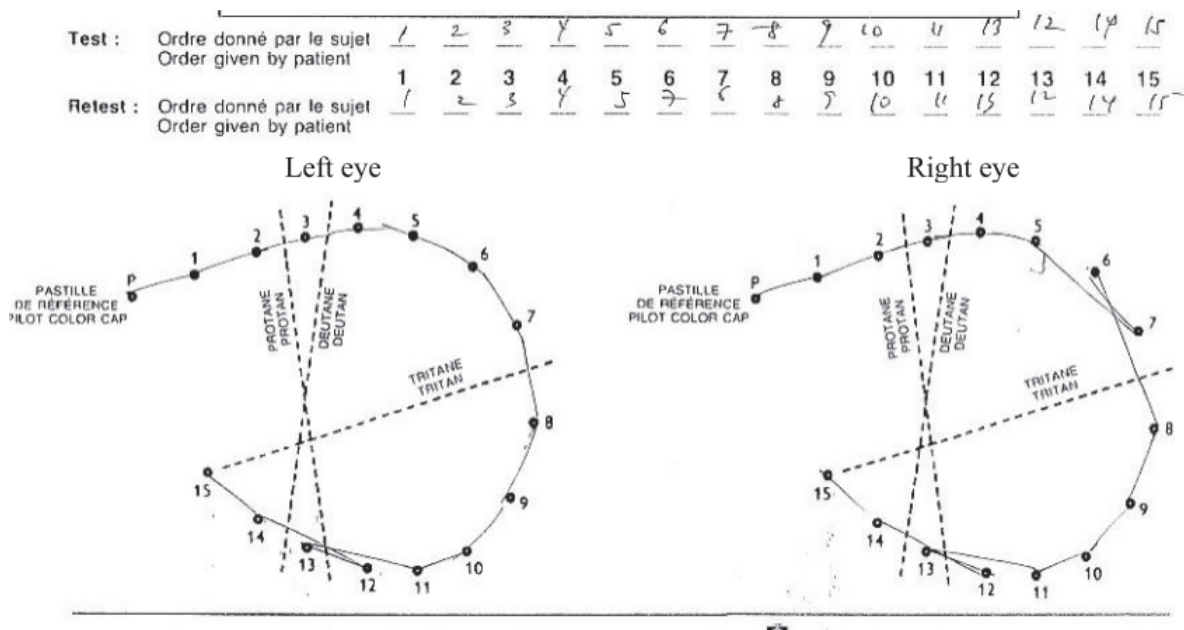


Figure 3: Farnsworth D-15 Hue Test at 2 months after discontinuation of ethambutol showing normal color vision.

## DISCUSSION

Ethambutol is one of the first-line drugs for tuberculosis and *Mycobacterium avium complex* (MAC) infections. Optic neuropathy is a well documented side-effect of ethambutol. The incidence of this reaction is proportional to the dose of ethambutol and is observed in 15% of patients receiving 50 mg/kg per day, in 5% of patients receiving 25 mg/kg per day, and in less than 1% of patients receiving daily doses of 15 mg/kg.<sup>1</sup>

Early-onset toxicity is an idiosyncratic reaction and is generally irreversible while delayed-onset toxicity is dose dependent due to zinc-chelation property of the drug and is generally reversible. Frequently, patients who developed optic neuropathy have no detectable risk factors.<sup>2</sup>

According to Kollner's rule, retinal diseases cause blue-yellow colour vision defects whereas optic nerve diseases affect red-green discrimination.<sup>3</sup> This distinction is however not reliable.<sup>4</sup> Schneck *et al*<sup>5</sup> demonstrated that in optic neuritis, blue-yellow defects tend to be slightly more common in the acute phase of the disease.

Polak *et al*<sup>6</sup> reported that blue-yellow colour defects were the commonest and earliest defect in patients with ethambutol-induced optic neuropathy without any visual symptoms. Kumar *et al* noted that all the patients in their study had blue-yellow colour vision defects.<sup>2</sup>

Chest physicians, cardiologists, rheumatologists, urologists and internists routinely prescribe drugs that have the potential to cause ocular toxicity. Unfortunately, many non-

ophthalmologists especially internists use ISP to screen for acquired colour defects. In most instances, it is the only modality available outside the ophthalmology department to test for colour vision abnormalities.

The ISP were designed specifically for the screening of congenital red-green colour deficiencies. Therefore, the use of ISP for the detection of acquired blue-yellow colour deficiency is not appropriate. Moreover, unless a baseline ISP test was done, the ISP is not able to differentiate congenital from acquired red-green defects.

The Farnsworth Panel D-15 Hue test, on the other hand, is a quick and convenient way to screen for colour vision deficiencies. The test can be done at the bedside. It is as easy to administer as the ISP test. It can differentiate congenital from acquired colour vision defects. The severity of colour defect was reflected by the number of crossing errors in the chart.<sup>7</sup>

For congenital colour defects, the patterns of the dichotomous analysis chart are very precise.<sup>4</sup> In our patient, the dichotomous analysis patterns are irregular and asymmetry. This is characteristics for acquired colour defect, where the eyes were affected bilaterally but with varying severity.

Subtle blue-yellow defects can only be detected with the Lanthony Desaturated D-15 Test.<sup>8</sup> However, there is considerable within-subject variability in test results. Lanthony Desaturated D-15 Test can be complicated by the wide variety of fine colour discrimination abilities in people with normal colour vision. Subtle loss of colour discrimination can also occur with aging.<sup>9</sup>

Ethambutol toxicity can occur even at the lowest recommended dosage levels.<sup>10</sup> Vision loss can be severe and permanent.<sup>2</sup> Early detection and immediate therapy discontinuation are the only effective management that can halt the progression of vision loss and allow recovery of vision.<sup>8</sup>

In our patient the ethambutol ocular toxicity was diagnosed by detecting blue-yellow colour defect using Farnsworth Panel D-15 hue test, and the drug was immediately discontinued. A repeat test after 2 months showed complete recovery of blue-yellow colour defect. Thus, this case report illustrates the importance of regular monitoring of patients receiving ethambutol for blue-yellow defect using the Farnsworth Panel D-15 hue Test.

#### References

1. Petri WA, Chapter 48: Antimicrobial Agents. In: Hardman JG, Limbrid LE, Gillman AG. Goodman and Gillman's The Pharmacological Basis of Therapeutics, 10<sup>th</sup> edition, New York, McGraw-Hill, 2001, pg 1280.
2. Kumar A, Sandramouli S, Verma L, *et al*. Ocular ethambutol toxicity: is it reversible? *J Clin Neuro-ophthalmol*. 1993;13(1):15-17
3. Vander JF, Gault JA. Ophthalmology Secrets, 2<sup>nd</sup> edition. Pennsylvania: Mosby Elsevier, 2002, pg 1.
4. American Academy of Ophthalmology. Basic Science and Clinical Course. Section 12: Retina and Vitreous. San Francisco: American Academy of Ophthalmology, 2005, pg 44.
5. Schneck ME, Hargerstrom-Portney G. Color vision defect type and spatial vision in the optic neuritis treatment trial. *Invest Ophthalmol Vis Sci*. 1997;38(11):2278-89
6. Polak BC, Leys M, van Lith GH. Blue-yellow colour vision changes as early symptoms of ethambutol ocular toxicity. *Ophthalmologica* 1985;191(4):223-6
7. Good GW, Schepler A, Nichols JL. The reliability of the Lanthony Desaturated D-15 test. *Optom Vis Sci* 2005;82(12):1054-9
8. Chan RYC, Kwok AKH. Ocular toxicity of ethambutol. *Hong Kong Med J*. 2006;12(1):56-60
9. Lakowski R. Age and color vision. *Adv Sci* 1958;15:231-6
10. Melamud A, Kosmorsky G, Lee MS. Ocular ethambutol toxicity. *Mayo Clin Proc*. 2003;78(11):1409-11

### First case report of dengue in Malaya?

Skae FM. Dengue fever in Penang. *BMJ*. 1902;2:1581-2.

<http://www.pubmedcentral.nih.gov/picrender.fcgi?artid=2402112&blobtype=pdf>

## DENGUE FEVER IN PENANG.

BY F. M. T. SKAE, M.D.,  
Penang.

IN the BRITISH MEDICAL JOURNAL of July 12th, 1902, Dr. F. O. Stedman<sup>1</sup> gives an account of an epidemic of dengue fever in Hong Kong during the last three months of 1901, and Dr. Nightingale<sup>2</sup> reports its arrival in Bangkok in the beginning of December of the same year. The disease reached Penang from Singapore in the end of November or beginning of December, 1901 (my first case was on December 5th), was